



Gross Anatomical Studies of the Oropharyngeal Cavity in Eurasian Hobby (Falconinae: Falco Subbuteo, Linnaeus 1758)

Mohamed M. A. Abumandour^{1*}

¹Lecturer of Anatomy and Embryology, Faculty of Veterinary Medicine, Alexandria University

Abstract

There is no descriptive information about morphology of the oropharyngeal cavity of Eurasian Hobby. There is a common oropharyngeal cavity of Eurasian Hobby as reported in all avian species. The oral cavity of the Eurasian Hobby takes the triangular cone shape, while the roof of the oral cavity was formed by an incomplete hard palate, which presents by a long median choanal cleft, which connects the oropharynx to the nasal cavity. The choanal cleft divided into two parts; the rostral long narrow part and the caudal wide part. The infundibular cleft is very narrow, small, shorter, and more caudal midline slit-like opening. There were numerous conical backward papillae were scattered singly or arranged in five rows on the roof of the oral cavity. The arranged five rows of conical papillae; first row was the transverse huge caudomedially directed conical palatine papillae, encircled the choanal cleft. The second and third rows are longitudinal rows of the caudomedially directed papillae, were located parallel to the rostral narrow part of choana on each side. The fourth row is semicircular row of caudomedially directed conical palatine papillae, while the fifth row is oblique line of palatine papillae. The roof of pharynx has two semicircular papillary rows on the caudal border of the pharyngeal folds. The elongated tongue is non-protrusible and not extended to fill the limit of the lower beak. The laryngeal mound contains middle, elongated opening (glottis) which connected to the trachea and not guarded by the epiglottis.

Keywords: Eurasian hobby, Tongue, Beak, Lingual papillae.



This work is licensed under a [Creative Commons Attribution 3.0 License](https://creativecommons.org/licenses/by/3.0/)
Asian Online Journal Publishing Group

Contents

1. Introduction	81
2. Materials and Methods	81
2.1. Samples	81
2.2. For Gross Morphology	81
3. Results.....	82

* Corresponding Author

3.1. General Characters	82
3.2. Beak.....	82
3.3. Roof of the Oropharyngeal Cavity	82
3.4. Infundibular Cleft	83
3.5. Floor of the Oropharyngeal Cavity.....	83
3.6. Tongue.....	83
3.7. Laryngeal Mound (<i>Mons Laryngealis</i>).....	83
4. Discussion	83
4.1. General Features.....	83
4.2. Beak.....	84
4.3. Roof of the Oropharynx.....	84
4.4. Floor of the Oropharynx.....	85
References	87

1. Introduction

Falconidae family was belonged to order *Falconiformes*, this family was divided into two subfamilies; *Polyborinae* (includes caracaras and forest falcons), and *Falconinae* (includes falcons, kestrels and falconets). The subfamily *Falconinae* has five genus; *Herpotheres*, *Spiziapteryx*, *Polihierax*, *Microhierax* and *Falco*. The Eurasian Hobby was one of 11 species of family *Falconidae* in Egypt and was belonged to Genus *Falco* (include, true falcons, hobbies and kestrels) and subgenus *Hypotriorchis* [1]. The Eurasian Hobby has two subspecies; *subbuteo* and *streichi* [2]. The morphology of the bird oropharynx gained special attention in earlier descriptions of Göppert [3] which compared this structure of numerous avian species. This study was later supported by McLelland [4] who described in detail the structure of the oropharynx of many domestic species such as fowl, duck and goose and described that the oral cavity and pharynx form a common chamber called the oropharynx as noted by [5-8]. The morphological features of the oropharyngeal cavity were studies in various avian species as noted by [9-13].

It is well known that the tongue of the bird is intimately related with the birds the problem of methods of food obtained so the tongue act many functions according to the methods of food obtained; serve as a probe or spear (as woodpecker), a sieieve (as ducks), a capillary tube (as sunbirds), a brush (as *Trichglossidae*), a rasp (as vulture), a barbed organ (as penguin) [14]. The differences of various feeding habits among birds, environmental conditions, dietary specialization and specific adaptation for the collection, manipulation or swallowing of food are reflected in the anatomy and functional characteristics of their tongue [15-21]. In our literature review, we could not find sufficient information about the *Eurasian Hobby* except [22] on the histomorphological studies of stomach. From the previous published data, we not find sufficient information about the oropharyngeal cavity and its structures of the Eurasian Hobby. In this study, our aim was to comparatively study the gross anatomical features of the oropharyngeal cavity in the Eurasian Hobby, in addition to reviewing the literature and comparing our findings with the literature.

2. Materials and Methods

2.1. Samples

The heads used in the present study were collected from 8 adult normal healthy Eurasian Hobbies weighing approximately 150 g, were captured from Desouk city, kafre El-sheik Governorate, Egypt. Then the birds were kept in individual cages, fed with new-born rats, chow for dogs and water adlibitum during 3 days at circadian time table (12 h of light and 12 h of dark).

2.2. For Gross Morphology

All Eurasian Hobbies were sedated by Rompun (Xylazine hydrochloride 20 mg/ml), then anaesthetized with chloral hydrate. After all the Eurasian Hobbies were anaesthetized, they were well bled via the common carotid artery (sexes and body weights were not recorded). The adult normal healthy Eurasian Hobbies of both sexes were used to demonstrate; the gross anatomical features of the oropharyngeal cavity. Four heads of the Eurasian Hobbies were used as fresh and four were formalized in a 10% formalin solution. To obtain good observation, we should open

the mouth cavity wider; the beak's angles were incised. Then anatomical position and shape of all the structures included in the oropharyngeal cavity were studied in details. Finally, measurements were carried out on beaks, tongue, choanal slit, infundibular opening and glottis by ruler. Then the gross morphological features of the oropharyngeal cavity with its all structures were examined in situ by the naked eyes, next dissected, and photographed by digital camera (Sony).

The anatomical nomenclature used was based on Nomina Anatomica Avium (NAA) [23].

3. Results

3.1. General Characters

As all birds, the oropharyngeal cavity of the Eurasian Hobby lacks a soft palate, and there is no any separation between the oral cavity and pharynx producing a common chamber (oropharynx), in which this common cavity extended from the beak to the esophagus. The oropharyngeal cavity consists of; the roof (formed by incomplete hard palate, include infundibulum slit) and the floor (formed by mandible, tongue and laryngeal mound). The lips and teeth are absent, in which their function replaced by the edges of the beak and the muscular stomach. The oral cavity of the Eurasian Hobby takes the triangular cone shape, with apex rostrally (fig.1 and 2).

3.2. Beak

The beak consists of the upper and lower beak (fig.1:1, 2). Both beaks are covered by a horny sheath, which is very hard and rigid. The basis of the upper beak is formed by the incisive bone while the lower beak by the rostral part of mandible. The size and shape of the beak are related not only to the type of food the bird eat but also to their method of food prehension, so the edges of both upper and lower beak are sharp and thin and have pointed end rostrally to related to its method of food obtained as the Eurasian Hobby was belonged to the carnivore's bird so their beak adapted to their nature of feeding habits. Upper beak is very black in color and much curved (convex dorsally) and very concave ventrally with its rostral end very sharp, and ventrally convex. The upper beak reaches to 2.5cm in length and connected caudally to horny yellowish lamellae which contain caudal to it, the external nares which not covered with operculum. Lower beak is concave in shape dorsally (to receive the tongue) and nearly straight ventrally to receive the sharp pointed upper beak and also connected caudally to the horny yellowish lamellae. The lower beak reaches to 1.5cm in length. The angular commissure between the upper and lower beak is covered with very thick horny yellowish lamellae. There is median transverse ridge on the inner surface of the lower beak which not present in the upper beak.

3.3. Roof of the Oropharyngeal Cavity

3.3.1. Palate

The roof of the oral cavity was formed by an incomplete hard palate (fig. 2 and 3). This palate presents by a long median cleft called choana (*choanal cleft, palatine cleft*) (fig.2 and 3:8, 9), which connecting the oral cavity to the nasal cavity. The choanal cleft reaches to 25ml in length and divided into two parts; the rostral narrow triangular part (14ml in length, 3ml in wide caudally and 0.1cm rostrally) and the caudal wide part (11ml in length and 4ml in wide middle part). Rostral to the choanal cleft, there is a shallow triangular median palatine swelling area (fig.2:a), which wide rostrally and pointed caudally and rich by small sized caudally directed conical papillae. In the region of the narrow part of the palatine cleft and a little apically to it, the somewhat concave roof of the oral cavity is separated from the edge of the upper beak by the very clear *lateral palatine ridges* (fig.2:4), (fig.3:7), which reach to 20ml in length and 2ml in thickness (at middle part). The part of the palate framed by the lateral palatine ridges is known as *choanal field* (fig.2:b), in which the shape of this area corresponds closely to the shape of the dorsum of the tongue.

There were numerous conical backwards directed papillae were scattered singly or arranged in rows; the surface of the incomplete hard palate have numerous scattered singly caudomedially directed conical palatine papillae without characteristic shape (fig.2:13), (fig.3:5). While the arranged conical palatine papillae are arranged in a five rows; the first papillary row is the transverse huge caudomedially directed conical palatine papillae, were arranged in shorter conical papillae encircled the choanal cleft (fig.3:1). The second and the third papillary rows are two longitudinal rows of the caudomedially directed papillae, were located parallel to the rostral narrow part of choana on each side (fig.2:5), (fig.3:2). The fourth papillary row is semicircular row of caudomedially directed largest conical palatine papillae (24–30 papillae) (fig.2:6) (fig.3:3), this row is convex rostrally and concave caudally, which begin

between the rostral and caudal parts of the choanal cleft. The fifth papillary row is oblique line of caudomedially directed palatine papillae (fig.2:7), (fig.3:4). A similar there are only one semicircular papillary row (7–14 very small papillae), was detected on the caudal border of the two oval pharyngeal folds (fig.2:11), (fig.3:6), while there is no any papilla around the infundibular cleft.

3.4. Infundibular Cleft

Just caudal to the choana there is an opening called the infundibular cleft (pharyngeal opening of auditory tube) (fig.2:12) (fig.3:11), which limited by the two oval pharyngeal folds (fig.2 and 3:10), this cleft situated in the roof of pharynx between the two pharyngeal folds. The infundibular cleft is very narrow, small, shorter, and more caudal midline slit-like opening common to the right and left auditory tubes, which reach to 2ml in wide and 8ml in long. There is a previous discussed semicircular papillary row, this row of papilla mark the end of pharyngeal cavity and the beginning of the esophagus. There is no any papilla around on the two oval pharyngeal folds. There is no also any scattered papillae on the roof and floor of the pharyngeal cavity.

3.5. Floor of the Oropharyngeal Cavity

It is concave triangular depression in shape, present between the rami of mandible of the lower beak which accompanied by the tongue. The floor of oral cavity is small than the roof and consists of mandible, tongue and laryngeal mound (fig.2, 3 and 4).

3.6. Tongue

The elongated tongue of Eurasian Hobby is lay approximately in the middle of the floor of the oropharynx which supported by a deliacted hyoid apparatus and fitting into the gap between the mandible, and play a major role in the moving the bolus within the oropharynx into esophagus while the choanal cleft is closed (fig.2 and 4). The Eurasian Hobbies tongue is non-protrusible, and not extended to fill the limit of the lower beak, in which reach to 25ml in the length. The tongue is formed of three part; the base (lingual root), body and the free end (lingual apex) (fig.2: T, R) (fig.4:Ta, Tb, Tr). The free end of the tongue is bifurcated into two pointed lateral small end (fig.2:14) (fig.4:Tf) and attached to the sublingual floor by the lingual frenulum, in which this free end cover mainly large part of the sublingual and prefrenulum part of the floor of the mouth. The papillary crest with one transverse papillary row of conical caudally directed lingual papillae was located between the lingual body and lingual root (Fig. 2 and 4:P). The papillary crest was "V" shape reaches to 5ml in width, so the lingual root nearly triangular shape with their apex rostrally. In the papillary crest, there were 12–14 large conical caudally directed lingual papillae. The conical papillae of both lateral borders of the papillary crest were very large and very pointed, while the conical papillae of the medial region of the papillary crest were smaller. Macroscopically, there were no papillae or other lingual projections on the dorsal surface of both the lingual body and root (Fig. 2 and 4:T).

3.7. Laryngeal Mound (*Mons Laryngealis*)

In the pharynx, caudally to the base of the tongue, there is elevated triangular area called the laryngeal mound (fig.2 and 4: L), with their apex cranially. The laryngeal mound contain middle, elongated opening called glottis or laryngeal cleft (fig.2 and 4:G), which connected the oropharyngeal cavity to the trachea and not guarded by the epiglottis. This opening reaches to 15ml in length and 3ml in wide (at its middle part). There are two transverse rows of large sized, caudally directed conical pharyngeal papillae; rostral and caudal row, which present at the caudal border of laryngeal mound (fig.2:13) (fig.2:Lp), in which the medial papillae were larger than the others. There were no papillae on the surface of the laryngeal mound or throughout both the lateral borders of the glottis (laryngeal cleft).

The morphometric data of all structures in the oropharyngeal cavity of the Eurasian Hobby are shown in [Table 1](#).

4. Discussion

4.1. General Features

There is adaptation between the habitats of birds with their feeding habits; in the air, on land and on and around fresh water and sea water with respect to food sources. Birds have different feeding habits, with corresponding differences in the structure of their oropharyngeal cavity, so the structure of the avian oropharyngeal cavity

frequently gives some clue to the principal diet and manner of feeding in each species, for example probe or spear in woodpeckers, sieve in ducks, capillary tube in sunbirds, brush in Trichglossidae, rasp in vulture and barbet in penguin. The boundaries and components of the oral and pharyngeal cavities of the ostrich agree with the general avian pattern as previously described [3, 4, 7, 24]. Our study agree with the classical anatomical descriptions of the avian oropharyngeal previously described by [4, 7, 8, 25-28] that, the oral cavity is characterized by the absence of a soft palate, so there is no obvious separation between the oral cavity and pharynx but there is obvious morphological constriction separating the mouth from the pharynx. The roof of oral cavity formed of incomplete hard palate, because of the presence of a choanal slit that extends longitudinally in the midline of the caudal half of the palate which connects the oropharynx to the nasal cavity. However, [29] described a margin between both cavities at the level of the caudal lingual papillae in the mallard.

4.2. Beak

The wide variation in the morphology of the avian beak is related to the adaptation of strategies for obtaining food, feeding methods, and different kinds of food and climate conditions [19] as the upper and lower beaks of birds function as prehensile organs and assist in the incomplete break-down of food [8], so there is species-specific in the shape of the beak for example; In the present study in Eurasian Hobby, the upper and lower beak are covered by a horny sheath, which is very hard and rigid, in addition to the upper beak is much curved and very concave ventrally with its rostral end very sharp, while the lower beak is concave in shape dorsally to receive the tongue and nearly straight ventrally to receive the sharp pointed upper beak. The beak of partridge is curved, flat, hard with a sharp extremity [26]. In the fowl and pigeon, the beak is pointed and the hard horny sheath of the upper beak was extended in a hook beyond that of the lower beak, in which the edges of both the upper and lower sheaths are sharp, while in the duck and goose, the spoon-shaped beak is almost completely covered by a soft, yellow waxy skin and the point of beak is of different texture and forms a hard horny plate shaped like a finger nail [8]. In ostrich, [30] noted that the flat spoon-shaped beak is covered by a hard horny. In other groups of birds such as in; flamingos and anatids [31], emu [32] and ostrich [33] noted that the rostral mandibular tomia is serrated, in addition, the maxillary tomia are narrow, strong and sharp, while the finding in the emu and ostrich contrasts with the statement by [34, 35] that the bill in ratites is relatively less adapted and non-specialized because of its sole function of holding food and that the tomia are blunt and rounded, but [36] noted that the bill of the emu requires little strength because of their diet and that these birds only require the ability to ingest large objects. Our study agree with Crole and Soley [32] that, There is median transverse ridge on the inner surface of the lower beak which not present in the upper beak.

4.3. Roof of the Oropharynx

The classical anatomical descriptions of the roof of the oropharynx of Eurasian Hobby are nearly the same previously described and illustrated in many species of birds [4].

4.3.1. Anatomical Characteristics of the Palate

Our study agree with the previous published data [8, 25, 26, 37] that, the palate consists of two parts; the anterior and posterior part, the anterior part lies apical to the choanal slit and a posterior part is divided into two regions by the choanal cleft, but Eurasian Hobby palate has special character in which, in the anterior part, there is a median triangular area, which have a number of small sized caudally directed papillae. There is somewhat species-specific in the shape of the avian choanal cleft for example; in our work, there is an elongated median choanal cleft, connecting the oropharynx to the nasal cavity and the choanal cleft divided into two parts; the long rostral narrow triangular part and the caudal wide part. Palatine cleft is very long in fowl and pigeon but short in duck and goose [8], while in the African pied crow the choanal cleft is consists of a narrow rostral portion and an enlarged caudal portion [38]. [27, 28] noted that the choana in the ostrich is very short and restricted to the caudal aspect of the palate, and the choana formed inverted V-shaped depression, as other species such as herons and ducks [4], while [27] added that the choanal cleft may take the bell-shape. Our study agree with Erdogan and Alan [11] in magpie and raven that, there are numerous conical backwards directed papillae were scattered singly or arranged in rows, in which the palatine surface have numerous scattered singly caudomedially directed conical papillae without characteristic shape. In the present study, the first record of the five arranged papillary rows of conical palatine papillae; the first transverse row is the huge caudomedially directed conical palatine papillae, encircled the choanal cleft as noted by [11, 39, 40]. The second and third longitudinal rows of caudomedially directed papillae, located parallel to the rostral narrow part of

choana on each side. The fourth semicircular row of caudomedially directed largest conical papillae, while the fifth oblique row of caudomedially directed papillae. Our study agree with [Erdogan and Alan \[11\]](#) that, the papillae organizing around choanal cleft obstruct escaping of foods into cleft and the others facilitate the movement of nutrients into the esophagus. [Tadjalli, et al. \[30\]](#) in ostrich, reported that the anterior two thirds of hard palate contain no papillae, while the caudal part of the palate contain short and slender papillae surrounding choanal cleft. In contrast to our result that noted the presence of the caudally directed papillae in the median triangular area of the anterior part of the palate [\[11, 41\]](#) in ostrich, emu, and raven and magpie, noted that the rostral part of palate lacks papillae, while in ostrich and in rhea [\[34\]](#) reported the completely absence of palatine papillae. The palate of fowls and pigeons has caudally pointing papillae arranged in several transverse rows, but the palate of goose has a median and 2-3 paramedian longitudinal rows of blunt papillae and in the duck, these papillae are confined to the apical region. In these species, moreover the duck and goose the edges of palate carry pointed papillae [\[4, 8\]](#).

There are species-specific in the presence or number and shape of the palatine ridges between the avian species for example; in the present study in Eurasian Hobby, in the region of narrow part of the palatine cleft, there is a very clear two lateral palatine ridges and these ridges not join apically, but [\[4\]](#) noted that in other avian species, the mucosa of the palate frequently forms lateral, median and intermediate ridges, while in ratites [\[30, 34, 35, 42\]](#) and [Sagsoz, et al. \[43\]](#) in the Chukar partridge, observed that the palatine mucosa formed a single median longitudinal ridge which extended the length of the palate rostral to the tip of the choana. Although, the palatine ridges were completely absent in in raven and magpie [\[11\]](#). Our study suggested that the ridges and different directed pointed papillae in palate play a role in transport of food as noted by [Nickel, et al. \[8\]](#). In our work, the part of the palate framed by the lateral palatine ridges is known as *choanal field*, in which the shape of this area corresponds closely to the shape of the dorsum of the tongue as noted [\[8\]](#).

4.3.2. Pharyngeal Folds and Infundibular Cleft (Plica Pharyngis)

In our work, the most obvious feature in the roof of the pharynx is the presence of two oval pharyngeal folds separated by very narrow, small, shorter, and more caudal midline slit-like opening (infundibular cleft, while infundibular cleft resemble tiny fissure [\[44\]](#). The present study agree with [Erdogan and Perez \[40\]](#) that, the caudal border of pharyngeal folds contain only one papillary row of very small papilla, which mark the end of pharyngeal cavity and the beginning of the esophagus. In contrast to our result, [\[30\]](#) mentioned that the ostrich characterized by the lack of this transverse row of papillae caudal to infundibular cleft. Choana and infundibular slit open together in budgerigar [\[45\]](#). In addition our study, observed that there is no any papilla around and on the two oval pharyngeal folds.

4.4. Floor of the Oropharynx

In our work, the floor of oral cavity takes the shape of triangular depression to adapt with the tongue shape and consists of mandible, tongue and laryngeal mound. In the ostrich, [\[30\]](#) noted that the floor of mouth is a concave depression, the shape of tongue is adapted to the lower beak and is therefore very variable [\[8\]](#). [Bailey, et al. \[46\]](#) in captive bustards reported that the tongue lying in the floor of the oropharyngeal cavity, in a fossa between the rami of the lower mandible.

4.4.1. Tongue

The shape of tongue in birds have two probabilities of adaption, the first probability, the tongue is closely related with the form of the lower beak [\[8, 26, 47-50\]](#), while the second probability, there is no any relation between the tongue shape and the size of lower beak, for example; The ratite is characterized by short tongue which described as a rudimentary tongues or vestigial organ and not adapted to the size of lower beak as in; cormorant *Phalacrocorax carbo* [\[51\]](#), in ostrich and rhea [\[10, 41, 52-54\]](#) or the elongated tongue in wood-peckers [\[55\]](#).

The shape of the tongue is species-specific among avian species, so there are several forms of the tongue shape to adapted eating habits, types of food, and lifestyle for example; the triangular form of the tongue is the most common among the avian species as noted by [Rossi, et al. \[26\]](#) in partridge, [\[26\]](#) in quail, [\[56\]](#) in chicken, and [Nazan, et al. \[37\]](#) in Marmara region sea gulls. In our study in Eurasian Hobby the tongue is elongated as noted in European magpie and common raven [\[11\]](#), moreover, an elongated and oval tongue is a characteristic feature in water birds, as duck and goose [\[17, 25, 57\]](#), however the tongue of Little Egret, black-crowned night heron, and green-backed heron which feeds on fish and frogs were needle-like or had a spearhead-like shape [\[58\]](#). In addition, there are different

shape of the tongue for example, in the pigeon, the tongue is narrow and broad, lancet-shaped in fowl [8], while the tongue of the Jungle Nightjar is a spearhead-like shape [59]. The tongue of the kakapo is relatively short and wide, whereas the tongue of kaka is comparatively long and narrows [39]. Bailey, et al. [46] in captive bustards reported that the tongue is arrow shaped with serrations along its edges. The ratite is characterized by short tongue as noted by [3, 27, 30, 60-63] that, the tongue is semicircular, short and broad. So our result suggest that the morphological differences and variations appearing in the tongue of avian species are directly associated with dietary specialization and food type they consume, and adaptation to environmental conditions surrounding them [17, 49, 50, 64].

Our work in the Eurasian Hobby agree with Erdogan and Alan [11] in magpie, [56] in chicken, [65] in penguin, and Santos, et al. [54] in Rhea Americana in the absence of the lingual median groove, but this groove is a characteristic feature in some avian tongue as in; White tailed eagle [64], Egyptian goose [57], southern lapwing [40], golden eagle [49], Northern goshawk [48], Middendorff's bean goose [17] and in Nutcracker [66]. While in the anterior part of the little tern tongue, there is a median line [67]. On the dorsal surface of the short tongue of the cormorant, in the midline a crest is found, resembling a ridge, reaching both ends of the organ [51].

There is a species-specific in the shape of the lingual apex, in which in our study we suggest that the shape of the lingual apex exhibit adaptations specific for the collection, manipulation of foods, eating habits and lifestyle in different environments. For example; The characteristic feature of the bifurcated lingual apex is only encountered in few avian species as; in our study in Eurasian Hobby, [11] in magpie, [45] in duck and goose, [48] in Peregrine falcon and Common kestrel, [68] in owl, [69] in northern fur seal, [70] in red jungle fowl, [71] in beaver, and Iwasaki [67] in little tern. However, in Nutcracker [66] noted that the tongue have a pair of dagger-like processes, modified "lingual nail" that plays a key role in levering up and shelling seeds, and moving them over the lingual median sulcus. Moreover, in birds whose tongues are used for collecting foods, the tongue can be extended from the oropharyngeal cavity and tongues typically have lateral barbs, needle-like processes at the lingual apex [16, 18, 55, 72]. In addition, there are different shapes of the lingual apex such as; a pointed lingual apex in chicken [56], in adult zebra finch [73] and El-Bakary [74] in hoopoe, round flat lingual apex in goose, swans, spot-billed duck and quail [17, 50, 75-77], a blunt round apex in male Ostrich [10], an oval-shaped apex in raven [11]. Our work in Eurasian Hobby agrees with [8, 45, 46, 70, 78, 79], that the tongue is non-protrusible and not extended to fill the limit of the lower beak. However, in *lamellirostres* and white tailed eagle, the tongue is completely fills the floor of mouth [8, 64]. Whoever in many birds, as humming birds, insectivorous and sunbirds the tongue is long and protrusible for collecting the food particles as noted by King and Mclelland [44] and Igwebuike and Eze [38] in the tongue of African pied crow. Our study suggest that the characteristic features of the protrusible or not of the avian tongue is adapted for the eating habits as noted in; tongues used to manipulate food, such as in piscivorous species, are non-protruding and covered with stiff, sharp, caudally directed papillae [80, 81] and a good example of such adaptation is the tongue of the woodpecker, which extends a considerable distance from the oropharyngeal cavity to catch insects and larvae inside trees [44, 82]. The most distinguishing structure on the lingual body in Eurasian Hobby as in most birds is the presence of conical papillary crest that separated lingual body from the lingual root and was pointed caudally, and this crest carrying the caudally directed conical papillae which play a major role in the directing foods to the esophagus and also plays an important role in preventing the regurgitation of small and large nutrients guiding to oesophagus from the lingual surface as noted by [11, 40]. The presence of rudimentary tongue without papillary crest in ratite birds was explained by the evolutionary acquisition of the ability to swallow voluminous foods [4]. Instead of a papillary crest, the entire surface of the penguin tongue possessed giant conical papillae ranging from the lingual apex to the laryngeal eminence, which is thought to be adaptive for manipulating food [83].

The variations in the shape of the conical papillary crest with related to nature of food; for example the "V" shaped papillary crest is the common among avian species as noted in; our study in Eurasian Hobby, White tailed eagle [64], quail [49], Egyptian goose [57], Middendorff's bean goose [17], and in zebra finch [73], while the papillary crest take the shape of a letter "W" shaped row in hoopoe [74]. The papillary crest take the shape of a transversal orientation in the southern lapwing [40] and in magpie and raven [11], moreover, the papillary crest was well developed in two transverse rows in anseriforms, whereas it was composed of one transversal row in species of the Corvidae family [11]. In quail [49] and chicken [56] there is also an additional row composed only of two large papillae located right behind the main conical papillary row in each half of the tongue. Moreover, Erdogan and Alan [11] in magpie and raven noted that there is an irregular additional row consisting of large and small conical papillae, locating just rear of the main papillary row. In contrast to several birds, the papillary crest is absent in Japanese pygmy woodpecker [55], ostrich [52, 53], emu [84], and Rhea Americana [54].

It is well known that, there are variations among bird's species in their nature of food, feeding sources and habits, even they all possess papillary crest of different shape, a finding agree with [Erdogan and Alan \[11\]](#) that, there is no absolute relation between the presence of papillary crest and their nature of food, methods of food intake, feeding sources and habits, this suggestion clear in that, there are avian tongue have a papillary crest, although, these birds are differences in the sources of food, feeding habits, and types of food as discussed also by [\[11-13\]](#), this examples are; White tailed eagle [\[64\]](#), little egret [\[85\]](#), little tern [\[67\]](#), long-legged buzzard [\[12\]](#), and cormorant [\[51\]](#) are predatory birds that mostly live on fish, Peregrine falcon and Common kestrel [\[48\]](#) are raptorial birds that predominantly feed on small animals. Hoopoe [\[74\]](#) is a species that lives on larva, lizard, insect, and geckoes. Moreover in, zebra finch [\[73\]](#), chicken [\[56\]](#), quail [\[49\]](#), Middendorff's bean goose [\[17\]](#), and nutcracker [\[66\]](#) eat mainly seeds and plants but sometimes also small invertebrates for nourishment. The magpie and raven live on seeds, fruits, beetles, small invertebrates, amphibians, reptiles, wastes, and carrions [\[86\]](#). Also, some birds live on seeds, plants, beetles, invertebrates, small vertebrates, waste and carrion such as, Magpies and ravens [\[11\]](#).

It is well documented that in many avian species, including domestic birds, the tongue is adorned with lingual papillae [\[3, 4, 8, 87-89\]](#). In our work, the tongue has one transverse row of lingual papillae pointed caudally toward the pharynx on the papillary crest, as in fowls and pigeons [\[8\]](#), African pied crow [\[38\]](#), and in bustards [\[46\]](#), while in duck and goose, in addition to this row of lingual papillae, there is another row of upright, horny papillae situated at the edges of the tongue. Transversal lingual papilla at caudal part of the tongue [\[8, 25, 79, 90, 91\]](#) and especially in ducks and geese horny papillae were reported [\[25, 90, 91\]](#) at sides of the tongue. However, in spite the lingual papillae were present no horny papillae were observed in sea gulls by [Nazan, et al. \[37\]](#). [Getty \[25\]](#) stated number of transversal lingual papillas about 30 and [Nazan, et al. \[37\]](#) in sea gulls observe 20-25 transversal lingual papillas. In penguins, the whole tongue is covered by large, spine-like caudally directed lingual filiform-like papillae, which are adapted to hold the slippery prey [\[89\]](#), while [\[79\]](#) noted that the tongues in *piscivorous* species are covered with stiff, sharp, caudally directed papilla. [Jackowiak and Godynicki \[64\]](#) in white tailed eagle and [Iwasaki \[67\]](#) in little tern, observed that in the posterior part of the tongue there is a row of large, conical papillae with sharp tips. [Catarina, et al. \[27\]](#) in ostrich confirm the observations of [\[3, 61\]](#) that the caudal aspect of the body of the tongue tapered bilaterally to form papillae-like extensions. In contrast to previous result, the lingual papillae of partridge [\[26\]](#) and in ostrich [\[30\]](#) are not visualized, so become clear that the lingual papillae are not a common in ratites [\[41\]](#). [Bailey, et al. \[46\]](#) in captive bustards reported that the tongue has on its lateral margins many pointed backwards papillae.

4.4.2. Laryngeal Mound (Mons Laryngealis)

The laryngeal mound as in our study and in all avian species is a raised structure lying immediately caudal to the tongue (close to lingual root) and carries on its rostral aspect the glottis [\[4, 27, 46\]](#). In our study the rostral $\frac{3}{4}$ of the glottis length was lay opposite the caudal wide part of the choana, while most avian species, the glottis typically lay directly opposite the caudal aspect of the choana as described [\[4\]](#). There are variation in the size and number of papillary row on the caudal border of the laryngeal mound as reported by [\[4, 8, 11, 38, 42, 45, 92\]](#). The present study noted that, there are two transverse rows of large sized, caudally directed conical pharyngeal papillae on the caudal border of laryngeal mound as reported by [\[4, 45\]](#), but our study added that there were no papillae throughout both lateral borders of the glottis (laryngeal cleft), however there are conical papillae were settled irregularly at the laryngeal mound and around glottis in goose [\[9\]](#). [Erdogan and Alan \[11\]](#) in raven and magpie noted that there is a only one row of caudally directed conical papillae at the border of glottic fissure and added that, there were vigorous papillary arrangements located not only paramedianly around the glottic fissure and extending transversely at both sides but also supporting the fissure caudally. [\[10, 30\]](#) noted that this area in ostrich is characterized by the absence of mechanical papillae, in contrast, there are reports that some ratite species, namely the greater rhea and kiwis, possess papillae [\[34, 61, 93, 94\]](#).

References

- [1] P. R. Myers, C. S. Parr, T. Jones, G. S. Hammond, and T. A. Dewey, *Subfamily Polyborinae (Caracaras and Forest Falcons)*. Animal Diversity Web. University of Michigan [Accessed 2009-08-15].
- [2] Bird Life International, "Falco subbuteo. IUCN red list of threatened species. Version 2013.2," *International Union for Conservation of Nature*, 2013.
- [3] Göppert, "Die bedeutung der zunge für den sekundären gaumen und den ductus naso-pahryngeus," *Morphologische Jahrbuch*, vol. 31, pp. 311-359, 1903.
- [4] J. McLelland, *Digestive system: In form and function in birds* (Ed. King AS, McLelland J). London: Academic Press, 1979.

- [5] W. Ellenberger and H. Baum, *Handbuch der vergleichenden anatomie der haustiere* 18. Aufl: Springer-Verlag, Berlin, 1943.
- [6] T. Koch and E. Rossa, *Anatomy of the chicken and domestic birds. Edited and translated from German by; Bernard H. Skold, Louis Devries.* Iowa: The Iowa State University Press Ames, 1973.
- [7] J. McLelland, *Aves digestive system. I Getty, R. Sisson and grossmans. The anatomy of the domestic animals*, 5th ed. vol. 2. Philadelphia, London, Toronto: W.B. Saunders Company, 1975.
- [8] R. Nickel, A. Schummer, and E. Seiferle, *Anatomy of the domestic birds. Translation by W.G.Siller and P.A.L.Wight. Verlag Paul Parey.* Berlin: Hamburg, 1977.
- [9] B. Onuk, R. M. Hazirolu, and M. Kabak, "The gross anatomy of larynx, trachea and syrinx in goose (Anser Anser Domesticus)," *Journal of the Faculty of Veterinary Medicine, Kafkas University*, vol. 16, pp. 443–450, 2010.
- [10] A. P. Pasand, M. Tadjalli, and H. Mansouri, "Microscopic study on the tongue of male ostrich," *European Journal of Biological Science*, vol. 2, pp. 24-31, 2010.
- [11] S. Erdogan and A. Alan, "Gross anatomical and scanning electron microscopic studies of the oropharyngeal cavity in the European magpie (Pica Pica) and the common raven (Corvus Corax)," *Microscopy Research and Technique*, vol. 75, pp. 379–387, 2012.
- [12] S. Erdogan, W. Perez, and A. Alan, "Anatomical and scanning electron microscopic investigations of the tongue and laryngeal entrance in the long-legged buzzard (Buteo Rufinus, Cretzschmar, 1829)," *Microscopy Research and Technique*, vol. 75, pp. 1245–1252, 2012.
- [13] S. Erdogan, H. Sagsoz, and M. E. Akbalik, "Anatomical and histological structure of the tongue and histochemical characteristics of the lingual salivary glands in the Chukar partridge (Alectoris Chukar, Gray 1830)," *British Poultry Science*, vol. 53, pp. 307–315, 2012.
- [14] N. E. R. El Bakary, "Scanning electron microscope study of the dorsal lingual surface of halcyon smyrnensis (White Breasted Kingfisher)," *Global Veterinaria*, vol. 9, pp. 192-195, 2012.
- [15] J. G. Harrison, *Tongue. In: Thomson, A. L. (Ed.): A new dictionary of birds.* London: Nelson, 1964.
- [16] A. S. King and J. McLelland, *Birds, their structure and function*, 2nd ed. London: Baillière Tindall, 1984.
- [17] S. Iwasaki, A. Tomoichiro, and C. Akira, "Ultrastructural study of the keratinization of the dorsal epithelium of the tongue of middendorff's bean goose, anser fabalis middendorffii (Anseres, Anatidae)," *Anatomical Record*, vol. 247, pp. 149–163, 1997.
- [18] P. D. Sturkie, *Sturkie's avian physiology*, 5th ed. London, Boston, New York, Sydney, Toronto: Academic Press, San Diego, 2000.
- [19] S. Iwasaki, "Evolution of the structure and function of the vertebrate tongue," *Journal of Anatomy*, vol. 201, pp. 1-13, 2002.
- [20] S. Emura, T. Okumura, and H. Chen, "Comparative studies of the dorsal surface of the tongue in three avian species by scanning electron microscopy," *Okajimas Folia Anatomica Japonica*, vol. 86, pp. 111-115, 2010.
- [21] S. Erdogan and S. Iwasaki, "Function-related morphological characteristics and specialized structures of the avian tongue," *Annals of Anatomy, 2013 in Press. Doi: <http://dx.doi.org/10.1016/j.aanat.2013.09.005>*, 2013.
- [22] M. M. A. Abumandour, "Histomorphological studies on the stomach of Eurasian hobby (Falconinae: Falco Subbuteo, Linnaeus 1758) and its relation with its feeding habits," *Life Science Journal*, vol. 11, 2014.
- [23] J. J. Baumel, S. A. King, J. E. Breazile, H. E. Evans, and J. C. V. Berge, *Handbook of avian anatomy: Nomina anatomica avium*, 2nd ed. Cambridge: Nuttall Ornithological Club, 1993.
- [24] A. J. Bezuidenhout, *The OSTRICH biology, production and health, Edited by D.C.Deeming (Anatomy by A.J.Bezuidenhout). Hatchery consulting and research wallingford.* Oxon, UK: University of Manchester, 1999.
- [25] R. Getty, *Sisson and grossmans, the anatomy of the domestic animals*, 5th ed. vol. 2. London: W.B. Saunders Company, 1975.
- [26] J. Rossi, M. Silvana, O. Daniela, C. Cruz, V. Franzo, and S. Alex, "Morphology of beak and tongue of partridge *rhyngotus rufescens*," *Ciência Rural, Santa Maria*, vol. 35, pp. 1098-1102, 2005.
- [27] T. Catarina, N. R. Marcio, T. S. John, and B. G. Herman, "Gross anatomical features of the oropharyngeal cavity of the ostrich (Struthio Camelus)," *Pesq. Vet. Bras. Junho.*, vol. 31, pp. 543-550, 2011.
- [28] M. N. Rodrigues, C. N. Tivane, R. C. Carvalho, G. B. Oliveira, R. S. B. Silva, C. E. Ambrosio, M. F. Oliveira, and M. A. Miglino, "Gross morphology of rhea oropharyngeal cavity," *Pesq. Vet. Bras.*, vol. 32, pp. 53-59, 2012.
- [29] G. A. Zweers, A. F. C. Gerritsen, and P. J. Van Kranenburg-Voogd, "Mechanims of feeding of the Mallard (Anas Platyrhynchos L.; Aves, Anseriformes)," *Contr. Vert. Evol.*, vol. 3, pp. 436-439, 1977.
- [30] M. Tadjalli, S. H. Mansouri, and A. Poostpasand, "Gross anatomy of the oropharyngeal cavity in the ostrich (Struthio Camelus)," *Iranian Journal of Veterinary Research, Shiraz University.No. 4, Ser. No. 25*, vol. 9, 2008.
- [31] G. A. Clark, *Anatomia topographica externa. In: Handbook of avian anatomy: Nomina anatomica avium. (J. J. Baumel, A. S. King, J. E. Breazile, H. E. Evans and J. C. Vanden Berge eds)*, 2nd ed. Cambridge: Massachusetts: Nuttall Ornithological Club, 1993.
- [32] M. R. Crole and J. T. Soley, "Gross morphology of the intra-oral rhamphotheca, oropharynx and proximal oesophagus of the emu (Dromaius Novaehollandiae)," *Anat. Histol. Embryol.*, vol. 39, pp. 207–218, 2010.
- [33] C. N. Tivane, *A morphological study of the oropharynx and oesophagus of the ostrich (Struthio Camelus). MSc dissertation, faculty of veterinary science.* South Africa: University of Pretoria, 2008.
- [34] S. W. S. Gussekloo and G. R. Bout, "The kinematics of feeding and drinking in palaeognathous birds in relation to cranial morphology," *J. Exp. Biol.*, vol. 208, pp. 3395-3407, 2005.
- [35] S. W. S. Gussekloo, *Feeding structures in birds. In: Bels V. (Ed.). Feeding in domestic vertebrates: From structure to behavior.* Wallingford, UK: CABI Publishing, 2006.
- [36] S. J. J. F. Davies, "The food of emus," *Aust. J. Ecol.*, vol. 3, pp. 411–422, 1978.
- [37] G. I. Nazan, P. Gulsun, and O. K. Kifayet, "Anatomic investigations on digestive system of marmara region sea gulls," *Journal of Animal and Veterinary Advances*, vol. 9, pp. 1757-1760, 2010.
- [38] U. M. Igwebuike and U. U. Eze, "Anatomy of the oropharynx and the tongue of the african pied crow (Corvus Albus)," *Veterinarski Arhiv.*, vol. 80, pp. 523-531, 2010.
- [39] E. Kirk, R. Powlesland, and S. Cork, "Anatomy of the mandibles, tongues and alimentary tract of kakapo, with some comparative information from kea and kaka," *Notornis*, vol. 40, pp. 55-63, 1993.

- [40] S. Erdogan and W. Perez, "Anatomical and scanning electron microscopic characteristics of the oropharyngeal cavity (Tongue, Palate and Laryngeal Entrance) in the Southern lapwing (Charadriidae: Vanellus Chilensis, Molina 1782)," *Acta Zoologica (Stockholm)*, vol. IN Press, 2014.
- [41] M. R. Crole and J. T. Soley, "Morphology of the tongue of the emu (Dromaius Novaehollandiae). I. Gross anatomical features and topography," *Onderstepoort J Vet Res.*, vol. 76, pp. 335-345, 2009.
- [42] A. Cevik-Demirkan, R. M. Hazirog˘lu, and I. I. Ku˘rtu, "Gross morphological and histological features of larynx, trachea and syrinx in Japanese quail," *Anat Histol Embryol.*, vol. 36, pp. 215-219, 2007.
- [43] H. Sagsoz, S. Erdogan, and M. E. Akbalik, "Histomorphological structure of the palate and histochemical profiles of the salivary palatine glands in the Chukar partridge (Alectoris Chukar, Gray 1830)," *Acta Zoologica (Stockholm)*, vol. In Press, pp. 1-10, 2012.
- [44] A. S. King and J. Mclelland, *Birds, their structure and function*, 2nd ed. London: Baillière Tindall, 1984.
- [45] K. M. Dyce, W. O. Sack, and C. J. G. Wensing, *Text book of veterinary anatomy*. Philadelphia: Saunders, 2002.
- [46] T. A. Bailey, E. P. Mensah-brown, J. H. Samour, J. Naldo, P. Lawrence, and A. Garner, "Comparative morphology of the alimentary tract and its glandular derivatives of captive bustards," *J. Anat.*, vol. 191, pp. 387-398, 1997.
- [47] S. Emura, T. Okumura, and H. Chen, "SEM studies on the connective tissue cores of the lingual papillae of the Northern Goshawk (Accipiter Gentilis)," *Acta Anat Nippon.*, vol. 83, pp. 77-80, 2008.
- [48] S. Emura, T. Okumura, and H. Chen, "Scanning electron microscopic study of the tongue in the peregrine falcon and common kestrel," *Okajimas Folia Anat Jpn*, vol. 85, pp. 11-15, 2008.
- [49] A. Parchami, R. A. F. Dehkordi, and S. Bahadoran, "Fine structure of the dorsal lingual epithelium of the common quail (Coturnix Coturnix)," *World Appl Sci J.*, vol. 10, pp. 1185-1189, 2010.
- [50] A. Parchami, R. A. F. Dehkordi, and S. Bahadoran, "Scanning electron microscopy of the tongue in the golden eagle aquila chrysaetos (Aves: Falconiformes: Accipitridae)," *World J Zool.*, vol. 5, pp. 257-263, 2010.
- [51] H. Jackowiak, W. Andrzejewski, and S. Godynicki, "Light and scanning electron microscopic study of the tongue in the cormorant phalacrocorax carbo (Phalacrocoracidae, Aves)," *Zool Sci.*, vol. 23, pp. 161-167, 2006.
- [52] H. Jackowiak and M. Ludwig, "Light and scanning electron microscopic study of the structure of the ostrich (Strutio Camelus) tongue," *Zool Sci.*, vol. 25, pp. 188-194, 2008.
- [53] P. Guimara˘es, R. Mari, H. Silva De Carvalho, and L. Watanabe, "Fine structure of the dorsal surface of ostrich's (Struthio Camelus) tongue," *Zool Sci.*, vol. 26, pp. 153-156, 2009.
- [54] T. C. Santos, K. Y. Fukuda, J. P. Guimara˘es, M. F. Oliveira, M. A. Miglino, and L. Watanabe, "Light and scanning electron microcopy study of the tongue in Rhea Americana," *Zool Sci.*, vol. 28, pp. 41-46, 2011.
- [55] S. Emura, T. Okumura, and H. Chen, "Scanning electron microscopic study of the tongue in the Japanese pygmy woodpecker (Dendrocopos Kizuki)," *Okajimas Folia Anat Jpn*, vol. 86, pp. 31-35, 2009.
- [56] S. Iwasaki and K. Kobayashi, "Scanning and transmission electron microscopical studies on the lingual dorsal epithelium of chickens," *Acta Anat Nippon*, vol. 61, pp. 83-96, 1986.
- [57] S. M. Hassan, E. A. Moussa, and A. L. Cartwright, "Variations by sex in anatomical and morphological features of the tongue of Egyptian goose (Alopochen Aegyptiacus)," *Cells Tissues Organs.*, vol. 191, pp. 161-165, 2010.
- [58] S. Emura, "SEM studies on the lingual dorsal surfaces in three species of herons (In Japanese)," *Medicine and Biology*, vol. 153, p. 423-430, 2009.
- [59] S. Emura, T. Okumura, and H. Chen, "Scanning electron microscopic study of the tongue in the jungle nightjar (Caprimulgus Indicus)," *Okajimas Folia Anat. Jpn*, vol. 86, pp. 117-120, 2010.
- [60] J. E. Duerden, "Experiments with ostriches. XX. The anatomy and physiology of the ostrich: C. The internal organs, Part I," *Agricultural Journal of the Union of South Africa* 3, 492-507, Edited by Deeming D.C. (1999), *the Ostrich Biology, Production and Health*, 1912.
- [61] R. Faraggiana, "Sulla morfologia della lingua e del rialzo laringeo di alcune specie di Uccelli Ratiti e Carenati non comuni," *Bollettino dei Musei di Zoologia e Anatomia Comparata, Universita˘ di Torino*, vol. 43, pp. 313- 323, 1933.
- [62] M. E. Fowler, "Comparative clinical anatomy of ratites," *J. Zoo Wild. Med.*, vol. 22, pp. 204-227, 1991.
- [63] C. A. Tomlinson, *Feeding in palaeognathous birds. In: Schwenk K. (Ed.), Feeding: Form, function, and evolution in tetrapod vertebrates*. San Diego: Academic Press, 2000.
- [64] H. Jackowiak and S. Godynicki, "Light and scanning electron microscopic study of the tongue in the white tailed eagle (Haliaeetus Albicilla, Accipitridae, Aves)," *Ann. Anat.*, vol. 187, pp. 251-259, 2005.
- [65] K. Kobayashi, M. Kumakura, K. Yoshimura, M. Inatomi, and T. Asami, "Fine structure of the tongue and lingual papillae of the penguin," *Arch Histol Cytol.*, vol. 61, pp. 37-46, 1998.
- [66] H. Jackowiak, K. Skiersz-Szewczyk, S. Z. Kwiecin, S. J. Trzcielina, and S. Godynicki, "Functional morphology of the tongue in the nutcracker (Nucifraga Caryocatactes)," *Zool Sci.*, vol. 27, pp. 589-594, 2010.
- [67] S. Iwasaki, "Fine structure of the dorsal lingual epithelium of the little tern, sterna albifrons pallas (Aves, Lari)," *J. Morphol.*, vol. 212, pp. 13-20, 1992.
- [68] S. Emura and H. Chen, "Scanning electron microscopic study of the tongue in the owl (Strix Uralensis)," *Anat Histol Embryol.*, vol. 37, pp. 475-478, 2008.
- [69] S. Emura, A. Tamada, D. Hayakawa, H. Chen, and S. Shoumura, "SEM study on the dorsal lingual surface of the northern fur seal, Callorhinus ursinus (In Japanese)," *Mammalian Science*, vol. 41, pp. 187-194, 2001.
- [70] K. K. Kadhim, A. B. Zuki, S. M. A. Babjee, M. M. Noordin, and M. Zamri-Saad, "Morphological and histochemical observations of the red jungle fowl tongue gallus gallus," *African Journal of Biotechnology*, vol. 10, pp. 9969-9977, 2011.
- [71] J. Shindo, K. Yoshimura, and K. Kobatashi, "Comparative morphological study on the stereo-structure of the lingual papillae and their connective tissue cores of the American beaver (Castor Canadensis)," *Okajimas Folia Anat. Jpn.*, vol. 82, pp. 127-138, 2006.
- [72] W. J. Bock, "Functional and evolutionary morphology of woodpeckers," *The Ostrich*, vol. 70, pp. 23-31, 1999.

- [73] R. A. F. Dehkordi, A. Parchami, and S. Bahadoran, "Light and scanning electron microscopic study of the tongue in the zebra finch *Carduelis carduelis* (Aves: Passeriformes: Fringillidae)" *Slov Vet Res.*, vol. 47, pp. 139–144, 2010.
- [74] N. E. R. El-Bakary, "Surface morphology of the tongue of the hoopoe (*Upupa Epops*)," *J Am Sci.*, vol. 7, pp. 394–399, 2011.
- [75] S. Emura, "SEM studies on the connective tissue cores of the lingual papillae of swans (In Japanese)," *Medicine and Biology*, vol. 152, p. 379–385, 2008.
- [76] S. Emura, "SEM studies on the connective tissue cores of the lingual papillae of the spot-billed duck (In Japanese)," *Medicine and Biology*, vol. 153, pp. 63-69, 2009.
- [77] H. Jackowiak, K. Skiersz-Szewczyk, S. Godynicki, S. Iwasaki, and W. Meyer, "Functional morphology of the tongue in the domestic goose (*Anser Anser f. Domestica*)," *Anatomical Record*, vol. 294, pp. 1574–1584, 2011.
- [78] J. E. Duerden, "Experiments with ostriches. XVIII. The anatomy and physiology of the ostrich. A. The external characters," *Agric. J. Union S. Africa.*, vol. 3, pp. 22-29, 1912.
- [79] G. C. Whittow, *Sturkies avian physiology*, 5th ed. USA: Academic Press, 2000.
- [80] B. Campbell and E. Lack, *A dictionary of birds. Calton The British Ornithologists*, 1st ed. Calton, U.K: T. & A. D. Poyser, ISBN 10: 0856610399 ISBN 13: 9780856610394, 1985.
- [81] B. Vollmerhaus and S. F. Verdauungsapparat, In: *Nickel R, Schummer E. Seiferle E, eds. Lehrbuch der anatomie der haustiere. Bd. 5. Anatomie der vögel*. Berlin: Parey, 1992.
- [82] R. Ryan, "Anatomy and evolution of the woodpecker's tongue. Available www.talkorigins.org/faqs/woodpecker/woodpecker.html [Accessed January 2013]," 2003.
- [83] M. E. Samar, R. E. Avila, S. P. De Fabro, and C. Centurion, "Structural and cytochemical study of salivary glands in the magellanic penguin *Spheniscus magellanicus* and the kelp gull *Larus dominicanus*" *Marine Ornithology*, vol. 23, pp. 154-156, 1995.
- [84] M. R. Crole and J. T. Soley, "Surface morphology of the emu (*Dromaius Novaehollandiae*) tongue," *Anat Histol Embryol.*, vol. 39, pp. 355-365, 2010.
- [85] M. I. Almansour and B. M. Jarrar, "Morphological, histological and histochemical study of the lingual salivary glands of the little egret, *egretta garzetta*," *Saudi J Biol Sci.*, vol. 14, pp. 75-81 2007.
- [86] M. Nogales and E. C. Herna ´ndez, "Diet of common ravens on El Hierro, Canary Islands," *J Field Ornithol.*, vol. 68, pp. 382-391, 1997.
- [87] L. L. Gardner, "The adaptive modifications and the taxonomic value of the tongue in birds," in *Proc. United States National Museum 67. Article 19*, 1926.
- [88] L. L. Gardner, "On the tongue in birds," *Ibis*, vol. 3, pp. 185-196, 1927.
- [89] K. Kobayashi, M. Kumakura, K. Yoshimura, M. Inatomi, and T. Asami, "Fine structure of the tongue and lingual papillae of the penguin," *Archivum Histologicum Cytologicum*, vol. 61, pp. 37-46, 1998.
- [90] A. Bahadir, B. Yildiz, A. Serbest, and O. Yilmaz, "Evcil Su Kuslarindan Yerli Kaz, Yerli Ordek ve Pekin ordeginin sindirim sistemleri uzerinde karsilastirmali makro-anatomik ve subgros arastirmalar. Bolu 1," *Bas Bolumu Uludag Univ Vet Fak Derg.*, vol. 11, pp. 11-20, 1992.
- [91] N. Dursun, *Evcil kuslarin anatomisi*. Turkey: Medisan Yayinevi, Ankara, 2002.
- [92] M. Kabak, I. O. Orhan, and R. M. Hazirolu, "The gross anatomy of larynx, trachae and syrinx in the long-legged buzzard (*Buteo Rufinus*)," *Anat Histol Embryol.*, vol. 36, pp. 27-32, 2007.
- [93] C. McCann, "The tongues of kiwis," *Notornis*, vol. 20, pp. 123-127, 1973.
- [94] T. C. A. Bonga, *Feeding in paleognathous birds. In: Feeding: Form, function, and evolution in tetrapod vertebrates (K. Schwenk ed)*. San Diego: Academic Press, 2000.

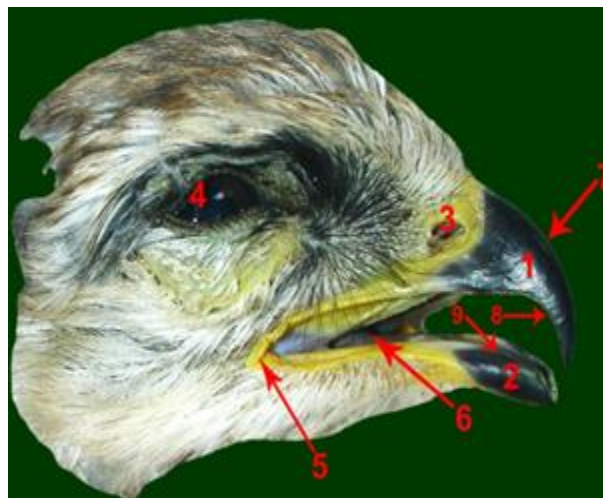


Figure-1. External anatomical appearance of Eurasian Hobby head to show

1-upper beak, 2-lower beak, 3- external nares without operculum, 4-eye, 5- mouth angle, 6- tongue, 7- culmen, 8- upper tomium, 9- lower tomium.

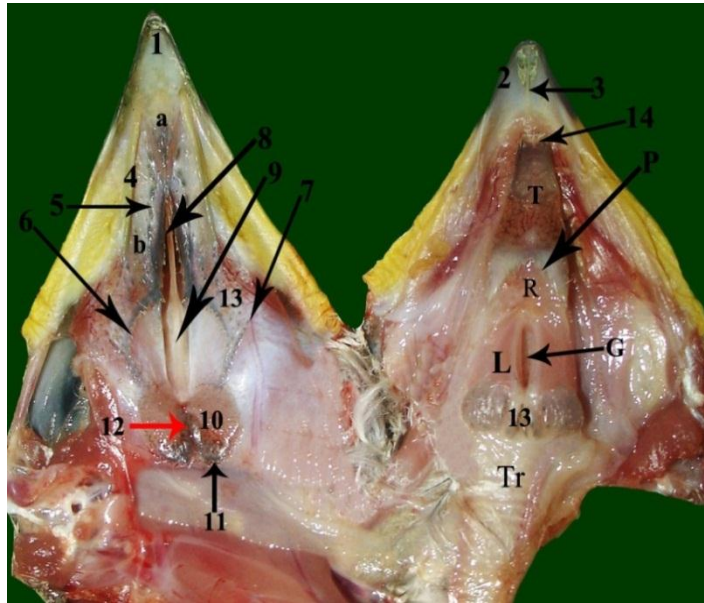


Figure-2. Gross anatomical features of the roof and floor of oropharyngeal cavity of falcon showing:

1-upper beak, 2- lower beak, 3-mandibular plate with transverse median ridge, 4- Lateral palatine ridge, 5- second and third longitudinal rows of palatine papillae, 6- fourth semicircular row of palatine papillae, 7- fifth oblique line of palatine papillae, 8-rostral narrow part of choana, 9- caudal wide part of choana, 10-pharyngeal folds, 11- semicircular papillary row on the caudal border of the two pharyngeal fold, 12- infundibular cleft, 13- Two transverse row of large sized, caudally directed conical pharyngeal papillae at caudal border of laryngeal mound, 14- bifurcated apex of tongue, a- a shallow median triangular swelling area, b-choanal cleft, T-tongue, L-laryngeal mound, Tr-Trachea, G-glottis, R-lingual root, P- papillary crest with one transverse row of conical caudally directed lingual papillae.

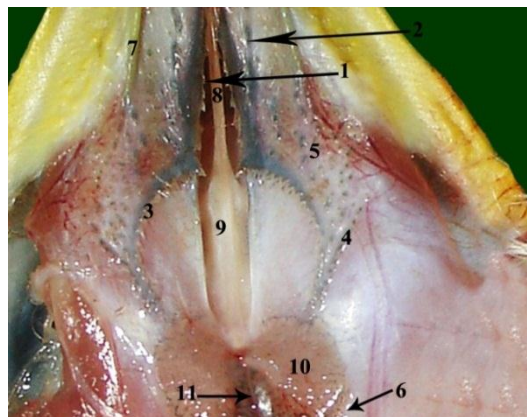


Figure-3. Anatomical appearance of the roof of the oropharyngeal cavity to show typical arrangement of the conical papillae:

1-The transverse huge row of caudomedially directed conical palatine papillae encircling the choanal cleft, 2- second or third longitudinal rows of caudally directed palatine papillae, 3- fourth semicircular row of caudomedially directed conical palatine papillae, 4- fifth oblique line of caudomedially directed conical palatine papillae, 5- Scattered caudomedially directed palatine papilla, 6- semicircular papillary pharyngeal row on the caudal border of the two pharyngeal fold, 7- Lateral palatine ridge, 8- rostral narrow part of the choana, 9- caudal narrow part of the choana, 10- pharyngeal fold, 11- infundibular cleft

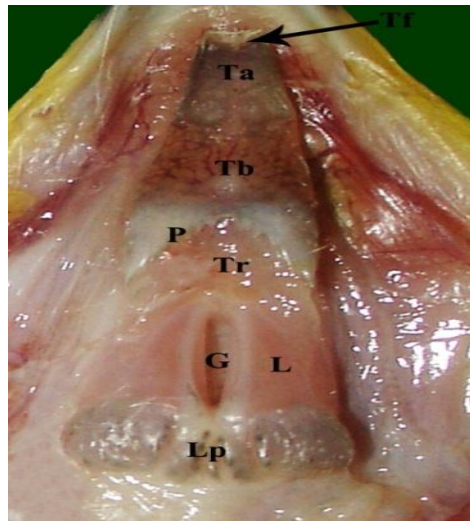


Figure-4. Floor of the oropharyngeal cavity to show arrangement of papillae:

Tf-bifurcated tip of the tongue, Lp-Rostral and caudal rows of laryngeal papilla, G-Glottis, Ta-lingual apex, Tb-lingual body, Tr-lingual root, L-Laryngeal mound, P- papillary crest with one transverse row of conical caudally directed lingual papillae

Table-1. To show the average measurements of the all structures in the oropharyngeal cavity (mm)

Beak	Upper beak	25±1	
	Lower beak	15±1	
Tongue	Total length of the tongue	25 ±0.25	
	Width of the tongue at	lingual apex	2.2 ±0.18
		lingual body	4 ±0.14
		lingual root	3.5 ±0.13
		papillary crest	5 ±0.19
	Thickness of the tongue at	lingual apex	1.2 ±0.04
		lingual body	2.3 ±0.06
		lingual root	3.8 ±0.08
Papillary crest	Length	8±1	
	Width	5±0.1	
glottis	Length	15 ±0.18	
	Width	3 ±0.1	
palate	Total length of palate	50 ±0.81	
	length of choanal cleft	25 ±0.16	
	Length of the rostral part of the choanal cleft	14 ±0.11	
	length of the caudal part of the choanal cleft	11 ±0.132	
	Width of rostral part of choanal cleft (caudally)	3 ±0.1	
	Width of rostral part of choanal cleft (rostrally)	1±0.03	
	Width of caudal part of choanal cleft (at its width part)	4 ±0.11	
	Length of lateral palatine ridge	20±1.5	
Width of lateral palatine ridge	2±0.05		
Infundibular cleft	Length	8 ±0.21	
	Width	2 ±0.14	
Glottis	Length	15±1	
	Width	3±0.21	

Views and opinions expressed in this article are the views and opinions of the authors, Journal of Life Sciences Research shall not be responsible or answerable for any loss, damage or liability etc. caused in relation to/arising out of the use of the content.